

Prosthetic Forearm Loop Graft versus Brachial-Basilic Arteriovenous Fisutla for Hemodialysis

¹Amr Saleh Elbahaey, ²Ahmed Aly Radwan

¹Department of Surgery, Vascular Surgery Unit, Cairo University,

²Department of Surgery, National Research Centre, Cairo University

ABSTRACT

Vascular access still remains the “Achilles’ heel” of the dialysis process. It seems that the native arterio-venous fistula that Brescia and Cimino described in 1966 still remains the first choice vascular access, however not all patients can be fit for that procedure. According to the KDOQI and European guidelines, when the patient vessels are not fit for radial-cephalic arterio-venous fistula (RCAVF) or brachial-cephalic arterio-venous fistula (BCAVF), the next recommended option is to either construct brachial-basilic arterio-venous fistula (BBAVF) or the use of a prosthetic implant. We studied 24 patients with End Stage Renal Disease (ESRD) who have inappropriate forearm vessels to construct autogenous fistula. **Patients and methods:** This is a randomized controlled study which included 24 patients. Eleven patients underwent forearm loop graft (the study group) and thirteen patients underwent brachial-basilic AVF with superficialization (control group). All patients in both groups were followed up over a period of 12 months at Kasr Alainy teaching hospital from July 2015 to July 2016. Our goal was to stand on the best hemodialysis option for ESRD patients with low quality forearm vessels regarding primary and assisted primary patency rates and complications. **Results:** Diabetes mellitus was found in nine patients (five were in the forearm loop graft group and the other four were in the BBAVF group). Hypertension was found in thirteen patients (seven were in the forearm loop graft group and six were in BBAVF group). In the forearm loop group, postoperative oedema developed in six patients, 6/11 (54.5%). In BBAVF group, postoperative oedema developed in two patients, 2/13 (15.4%). There was statistically significant difference in the incidence of post-operative oedema between the two groups ($p=0.05$). There was no significant statistical difference between the two groups regarding post operative venous hypertension, hematoma, infection, pseudoaneurysm, thrombosis and stenosis. No patients developed steal syndrome or heart failure in both groups. In the forearm loop group, the primary patency rate after one year was 81.8%. In the BBAVF, the 1ry patency rate was 92.3% in the 1st 6 months whereas the assisted 1ry patency rate was 100% in the same period. By the end of the 1st year, the 1ry patency rate was 84.6% and the assisted 1ry patency rate was 100% in the same period. **Conclusion:** The concept of “Whenever BBAVFs fail, it is still possible to create a prosthetic graft fistula in most patients” has to be changed to become “Whenever loop forearm prosthetic graft fails, it is still possible to have a BBAVF”.

Key Words: Forearm Loop, Brachial-Basilic, AVF

INTRODUCTION

The ambitious Dr. Willem Kolff constructed the first dialyzer (artificial kidney) in 1943. Since then, the progress of technology, the increased number of patients with End Stage Renal Disease (ESRD) and limited number of donors for kidney transplantation, dialysis has become a life saving procedure for around 2,522,000 ESRD patients. According to the global Fresenius Medical Care market survey ⁽¹⁾ that was done at 2013, there was an annual 6% growth rate of the ESRD patients in 150 countries included in that study.

Vascular access still remains the “Achilles’ heel” of the dialysis process ⁽²⁾. An ideal access delivers a flow rate to the dialyzer adequate for the dialysis prescription, has a long use-life, and has a low rate of complications (e.g. infection, stenosis, thrombosis, aneurysm, and limb ischemia). It seems that the native arteriovenous fistula that Brescia and Cimino described in 1966 still remains the first choice vascular access ⁽³⁾, however not all patients can be fit for that procedure. Despite the limitations of accurate vascular access outcome literature, compiling evidence exists that autogenous arterio-venous access has better long term patency rates and

requires fewer interventions to maintain patency than non autogenous arterio-venous access⁽⁴⁾.

According to the KDOQI and European guidelines, when the patient vessels are not fit for radial-cephalic arterio-venous fistula (RCAVF) or brachial-cephalic arterio-venous fistula (BCAVF), the next recommended option is to either construct brachial-basilic arterio-venous fistula (BBAVF) or the use of a prosthetic implant^(5,6). We studied 24 patients with ESRD who have inappropriate forearm vessels to construct autogenous fistula. Patients were divided into two main groups. The study group, that included 11 patients where loop forearm synthetic graft was done. The other 13 patients in the study had BBAVF. The two groups were followed for 12 months. Our goal was to stand on the best hemodialysis option for ESRD patients with low quality forearm vessels regarding primary and assisted primary patency rates and complications.

PATIENTS AND METHODS

This is a randomized controlled study which included 24 patients who were randomized using the block randomization technique (7). Eleven patients underwent forearm loop graft (the study group) and thirteen patients underwent brachial-basilic AVF with superficialization (control group). All patients in both groups were followed up over a period of 12 months at Kasr Alainy teaching hospital from July 2015 to July 2016.

All patients were subjected to history taking and clinical examination with emphasize on the age, comorbidities (hypertension, diabetes, cerebrovascular problems, ischemic heart disease and vasculitis), previous hemodialysis, AVF, and central catheters insertion for dialysis.

All patients were subjected to venous and arterial (if necessary) duplex and echocardiogram. Duplex ultrasound was done to assess the compressibility and diameter of superficial veins, patency of the axillary and subclavian veins (to exclude deep venous thrombosis and stenosis). Echocardiography was routinely done for all patients to assess their cardiac condition and to ensure that the ejection fraction is $\geq 35\%$.

Inclusion criteria:

1. Inability to do radio-cephalic or brachio-cephalic arterio-venous fistula, due to small diameter of the vein or radial artery insufficiency, or failure of both of them.

2. Adequate systemic blood pressure (systolic blood pressure >110 mmHg).
3. Adequate outflow vein (antecubital, basilic, commitment veins) diameter 3mm or more, 1 cm from surface, continuous with and has uninterrupted flow to the central veins as determined by Color flow Doppler ultrasound. Adequate central venous outflow.
4. EF $>$ or equal 35%.

For Forearm loop graft (the study group):
(Figures 1-4)

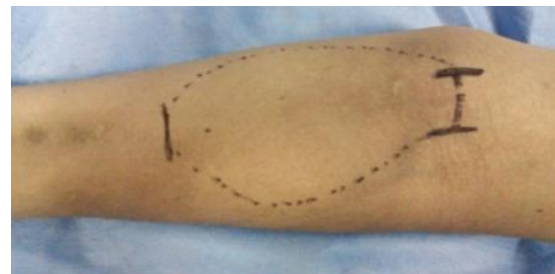

Fig. 1: The expected tunnel was drawn over the skin

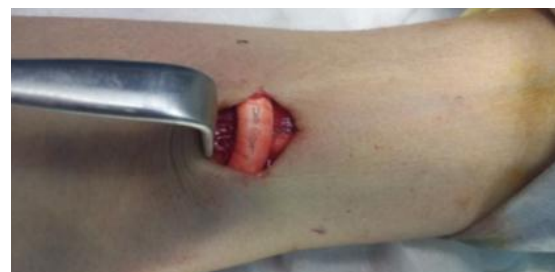

Fig. 2: The graft passed through the tunnel

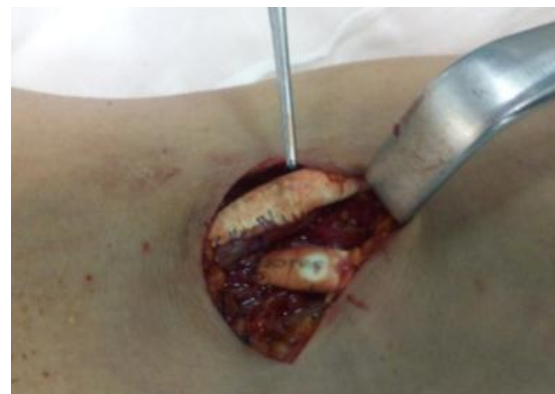

Fig. 3: The venous and arterial anastomoses

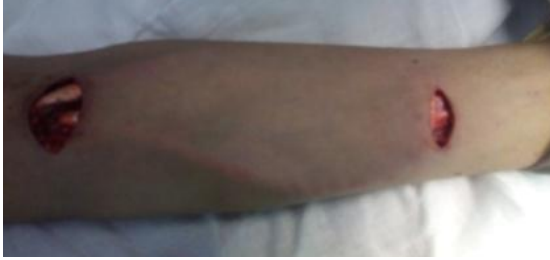

Fig. 4: The wounds before closure

Prophylactic antibiotics (e.g. cefuroxime 1.5 g i.v.) was administered, the patient was generally anaesthetised and positioned supine. Brachial artery and the median antecubital vein were dissected free. Notably, the median antecubital, basilic, cephalic, or deep veins can be used for the venous anastomosis; with the choice was based on the size and quality of the respective veins. The incision was transversely positioned 1 to 2 cm distal to the antecubital crease, and small skin flaps were elevated to expose the vessels. The proposed course of the prosthetic access was drawn over the forearm skin and the graft is draped over it to confirm that there was sufficient length. A small counter incision was made over the proposed course of the graft at approximately the 6 o'clock position with the antecubital crease being 12 o'clock. A tunneler was passed through the subcutaneous plane along the proposed access course, with an attempt to make the tunnel somewhat deeper near the antecubital incision and counter-incision than the rest of the course of the graft. A 6-mm expanded PTFE grafts was passed through the tunnel and then filled with saline to confirm that the graft followed a continuous, unobstructed course. The venous and arterial anastomoses were completed, sequentially using 5-0 expanded PTFE vascular suture. The wound was closed with subcutaneous polyglycolic acid sutures (vicryl® Jonson & Jonson Inc.USA), without drain insertion followed by occlusive dressing.

Control group:

All patients included in this group were subjected to the standardized brachial basilic AVF with superficialization technique⁽⁸⁾.

All patients in both groups were discharged 48 hours postoperatively, and skin stitches were removed after 14 days, and were instructed to start dialysis after 3 weeks in the forearm loop group and 6 weeks in the control group.

Clinical follow up was done one week after discharge from hospital and at 1,3,6,9 and 12 months thereafter. During the follow up visit, the patients were examined for the presence of oedema, seroma, infection, ecchymosis, hematoma, signs of venous hypertension, aneurysmal dilatation and steal syndrome.

Routine duplex was done at 1, 3, 6, and 12 months postoperatively to measure access blood flow (optimum flow is 500mL/min for native AVF and 800mL/min for prosthetic grafts) and to early detect any stenosis.

RESULTS

Our randomized controlled study included 24 patients. They were randomized into two groups. Eleven patients had forearm loop graft (study group) and 13 patients had brachial- basilic arterio-venous fistula (control group).

Eleven males (45.9%) and thirteen females (54.1%) of whom six males and five females underwent forearm loop graft and 8 females and 5 males underwent BBAVF. (**Table 1**)

Table 1: Sex distribution:

	<i>Forearm loop group</i>	<i>BBAVF</i>	<i>Total</i>	<i>%</i>
Male	6	5	11	45.9
Female	5	8	13	54.1
Total	11	13	24	100

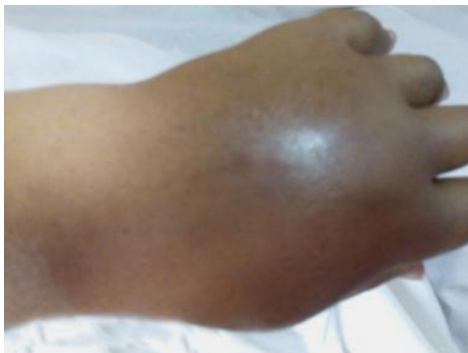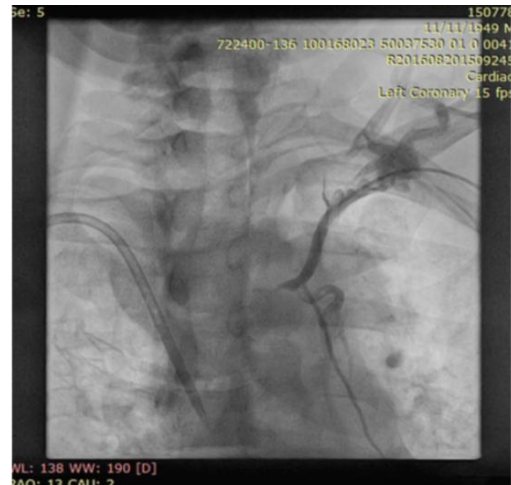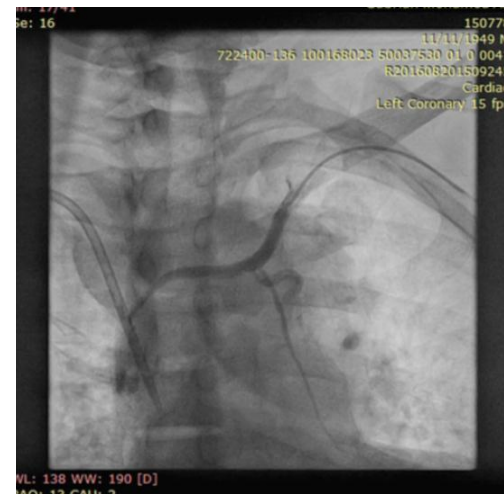
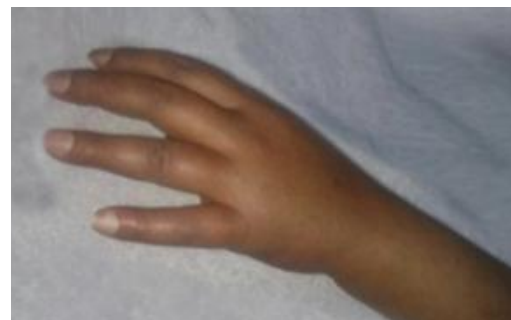The age of the patients of the forearm loop group ranged from 40 to 70 years (mean 56.8), while the age of the patients of the BBAVF group ranged from 19 to 69 years (mean 51.5). Comorbidities were diabetes mellitus, hypertension, ischemic heart diseases and stroke. Diabetes mellitus was found in nine patients (five were in the forearm loop graft group and the other four were in the BBAVF group). Hypertension was found in thirteen patients (seven were in the forearm loop graft group and six were in BBAVF group). The forearm loop group encompassed one ischemic heart disease patient and another one who had stroke several years before the procedure. (**Table 2**)

Table 2: Comorbidity:

	Forearm loop group		BBAVF group	
	No.	%	No.	%
Diabetes Mellits	5/11	45.5	4/13	30.8
Hypertension	7/11	63.6	6/13	46.2
IHD	1/11	9.1	----	----
Stroke	1/11	9.1	----	----

In the forearm loop group, postoperative oedema developed in six patients, 6/11 (54.5%). Oedema developed 2 to 3 days postoperatively at the site of the tunnel. After exclusion of central venous stenosis via duplex, patients were managed conservatively by limb elevation, hot fomentations and anti-inflammatory drugs. Oedema subsided after one month in 4 patients and 2 months in the other 2 patients. In BBAVF group, postoperative oedema developed in two patients, 2/13 (15.4%). It developed two days postoperatively at the site of the tunnel and was managed conservatively (after exclusion of central venous stenosis via duplex) and subsided two weeks thereafter. There was statistically significant difference in the incidence of post-operative oedema between the two groups ($p=0.05$).

In the BBAVF group, only one patient, 1/13, developed venous hypertension (7.7%). This patient suffered from hand oedema 4 months after surgery and duplex showed occlusion of the innominate vein. She underwent balloon dilatation. (Figures. 5-8) Oedema subsided gradually over a week following the procedure. There were no recorded cases of venous hypertension in the forearm loop group; and the difference was statistically insignificant ($p=0.3$).

**Fig.5:** Venous hypertension post BBAVF**Fig.6:** Angiography revealing occlusion of the innominate vein**Fig.7:** patent innominate vein post PTA**Fig. 8:** Improvement of venous hypertension post PTA

In the forearm loop group only a diabetic patient, 1/11, developed seroma (9.1%) one week postoperatively at the transverse segment of the graft (at the wound of the counter incision). She was managed by repeated dressings, compression and antibiotics. Seroma subsided over 2 weeks. After 2 months of effective dialysis through the constructed graft, the patient developed an abscess 3.7x1.5 cm on the transverse segment of the loop (the same site of previous seroma). The abscess was treated by limited drainage and the wound healed over 12 days of repeated dressing and antibiotics with continuation of hemodialysis from the graft for another month. Two weeks later, she developed severe infection at the site of the anastomosis and unfortunately, the fistula had to be ligated. There was no recorded cases of the same complication in the BBAVF group. The difference in the incidence of infection (one in the loop group vs zero in the BBAVF group) was statistically insignificant ($p=0.3$). (**Fig. 9**)

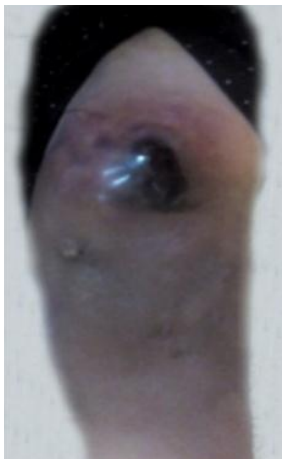

Fig.9: Infected graft of the forearm loop

In the forearm loop group, hematoma developed in four patients, 4/11, (36.4%) at the site of the tunnel and managed conservatively by antibiotics and hot fomentations. It subsided within 3 weeks. In BBAVF group, hematoma with overlying ecchymosis developed in two patients, 2/13, (15.4 %) at the middle of the wound and was managed conservatively and subsided over 2 months, the difference between both groups was statistically insignificant ($p=0.2$).

Only one patient, 1/13, (7.7%) developed pseudoaneurysm in the BBAVF group. This aneurysm was noticed during the radiological follow up at the third month. It was 0.5 cm in diameter and was followed up and monitored

without any intervention. There was no such complication in the forearm loop group. Again the difference between the two groups was statistically insignificant ($p=0.3$).

In the forearm loop group only one patient developed thrombosed graft, 1/11 (9.1%) after 4 months of successful dialysis. The incident happened two days after her last dialysis session. She underwent thrombectomy through exposure of both arterial and venous anastomoses, transverse graftotomy at the arterial side was done. Fogarty thrombectomy of the artery and the graft followed by insertion of 6 F sheath. Contrast injection through the 6F sheath revealed anastomotic stenosis at the venous side. A 0.035 wire (Terumo, Inc., Japan) crossed the lesion. Balloon angioplasty using 6mm x 40mm XXL® balloon (Boston Scientific Inc., USA) was then performed. However, after 1 month of efficient dialysis, the patient presented with thrombosed graft but this time the thrombectomy failed and she underwent brachio-axillary AVG.

In the BBAVF group, stenosis developed in the transposed basilic vein in four patients (30.7%), of which 2 stenoses (15.4%) were hemodynamically significant and the other two were not. One of the two hemodynamically significant stenoses was 5 cm long, 70% stenosis. It was diagnosed 3 months after surgery with access flow volume 213 ml/min, and inadequate dialysis. Through brachial artery access, 6 F sheath was inserted and a 0.035 wire (Terumo, Inc., Japan) crossed the lesion, and treated by 8mm x60mm XXL®balloon (Boston Scientific Inc., USA). The other hemodynamically significant stenosis (90%) was in distal segment of the basilic vein. It was diagnosed 9 months after surgery with access flow volume 350 ml/min, and inadequate dialysis. Through brachial artery access, 6 F sheath was inserted and a 0.035 wire (Terumo, Inc., Japan) crossed the lesion, and treated by 6mm x70mm XXL® balloon (Boston Scientific Inc., USA). The two hemodynamically insignificant stenoses were 45% and 40 %. They were diagnosed at the first 8 months of the follow up, but both patients had good access flow volume ranging between 1626ml/min to 2000 ml/min and adequate dialysis without any need for intervention. While in the forearm loop group only one patient developed stenosis and thrombosis, in the BBAVF group two patients developed significant stenosis and no one

developed thrombosis. There was no significant statistical difference between the two groups ($P=0.5$ and 0.3 , respectively).

In the forearm loop group, bleeding developed in only one patient (9.1%). The patient had an attack of bleeding 4 hours postoperative due to slipped ligature from a tributary to the basilic vein. Sewing of the base of the tributary was

done. Patient received 2 units of packed RBCs and was admitted into ICU for two days. In the BBAVF group, there was no recorded cases of postoperative bleeding. There was no statistically significant difference in the incidence of postoperative bleeding between the two groups ($P=0.3$). (Table 3)

Table 3: Complication:

	Forearm loop group		BBAVF group		P value
	No.	%	No.	%	
Oedema	6/11	54.5	2/13	15.4	0.05
Venous Hypertension	0/11	0	1/13	7.7	0.3
Seroma	1/11	9.1	0/13	0	0.3
Infection	1/11	9.1	0/13	0	0.3
Hematoma	4/11	36.4	2/13	15.4	0.2
Pseudoaneurysm	0/11	0	1/13	7.7	0.3
Thrombosis	1/11	9.1	0/13	0	0.3
Bleeding	1/11	9.1	0/13	0	0.3
Steal Syndrome	0/11	0	0/13	0	0
Heart failure	0/11	0	0/13	0	0
Stenosis	1/11	9.1	4/13	30.7	0.5

No patients developed steal syndrome or heart failure in both groups.

In the forearm loop group, nine patients, 9/11 (81.8%) had successful dialysis over the period of one year follow up. The primary patency rate after one year was 81.8%. While in the BBAVF group 13 patients underwent successful dialysis over the 1st 6 months with only one patient, 1/13 developed stenosis that needed PTA intervention. The 1ry patency rate was 92.3% in the 1st 6 months whereas the assisted 1ry patency rate was 100% in the same period. By the end of the 1st year, there was another patient who developed stenosis and underwent successful PTA. The 1ry patency rate after one year was 84.6% and the assisted 1^{ry} patency rate was 100% in the same period.

DISCUSSION

According to the latest statistics done by school of pharmacy and medicine, California University, U.S. Renal Data system, USRDS 2013⁽⁹⁾, the estimated number of population who are suffering from ESRD are 2 million people worldwide and the number of patients diagnosed

with the disease continues to increase at a rate of 5-7% per year.

Taiwan, Japan, Mexico, the United States, and Belgium currently have the highest prevalence of ESRD. Those patients are either on regular dialysis or on waiting list for kidney transplantation. Due to this increasing number of patients, their associated comorbidities and their increasing life expectancy, the search for alternative AVF other than the traditional ones is a challenging research topic for all vascular surgeons.

In our study, the BBAVF group had 38.5% males and 61.5% females. Their mean age was 51.5 and 30.8% were diabetic. On the other hand our forearm loop group had 54.5% males. The mean age among patients of that group was 56.8 and 45.5% were diabetics. The higher incidence of diabetes mellitus in the forearm loop group, being 14.7% more than the BBAVF group, could attribute to the higher incidence of infection among the former group (9.1% infection in the forearm loop group versus zero percent in the BBAVF group).

In our study 54.5% of cases of the forearm loop group developed postoperative oedema, whereas only 15.4% of the patients of the BBAVF

group developed the same complication. The difference of incidence of oedema between the two groups was statistically significant ($P= 0.05$), this significant difference may correlate with the higher flow across the loop graft than across the BBAVF and this reported incidence varies between different reports. Oedema developed in 54.5% of our cases of the forearm loop group, this was not correlating with what Dammers et al.⁽¹⁰⁾ and Georgiadis et al.⁽¹¹⁾ reported being 6% and 14 % respectively. While we had 15.4% incidence of postoperative oedema in the BBAVF group, Murphy et al.⁽¹²⁾ and Canbaz et al.⁽¹³⁾ had higher incidence 24% and 25.3%, respectively. Dix and khan⁽¹⁴⁾ had lower incidence of postoperative oedema (3.7%). In our management of this oedema we had excluded first the presence of overlooked central venous insufficiency before we went into conservative management. Again, the higher flow across the loop graft than across the BBAVF may explain the longer duration that the oedema took to resolve. It was 1-2 months in the former group and 2 weeks in the later group.

One patient in the forearm loop group developed stenosis at the graft venous anastomosis (9.1%). This patient presented by thrombosed graft and upon doing thrombectomy, this stenosis was found to be the culprit responsible for graft thrombosis. Thrombectomy followed by PTA were successful in bringing the graft to function again. Unfortunately this patient developed rethrombosis one month later and thrombectomy failed. This patient accounted for the 9.1% incidence of stenosis we had in the forearm loop group and another 9.1% of thrombosis in the same group. Our incidence of stenosis in the forearm loop group was lower than Sande et al.⁽¹⁵⁾, Rooijens et al.⁽¹⁶⁾ and Dammers et al.⁽¹⁰⁾ being 41%,30%, and 26% respectively. Similarly our incidence of thrombosis was lesser than what Keuter et al.⁽¹⁷⁾ and Rooijens et al.⁽¹⁶⁾ being 84% and 54% respectively. We had not encountered thrombosis among the BBAVF cases, while Murphy et al.⁽¹²⁾, Canbaz et al.⁽¹³⁾, Sande et al.⁽¹⁵⁾ and Dix and khan⁽¹⁴⁾ encountered incidence of 28.2%,22%,16.1%, and 9.7%, respectively. Our small sample size (24 cases in both groups) may stand behind the lower incidence of thrombosis.

We had 4 cases of stenosis in the transposed basilic vein (30.7%). Two were hemodynamically significant and the remaining two were not. PTA

without stenting had successfully treated the two hemodynamically significant stenoses. This incidence of stenosis (30.7%) in our BBAVF group was higher than reported by Dix and khan⁽¹⁴⁾, Sande et al.⁽¹⁵⁾ and Keuter et al.⁽¹⁷⁾ being 2.3%, 25.8%, and 39%, respectively. Inclusion of 2 cases of non hemodynamically significant stenosis (15.4%) may be responsible for our higher incidence rather than a true occurrence of stenosis.

We had no pseudoaneurysm in our forearm loop group (zero percent). This incidence was similar to what had been reported by Keuter et al.⁽¹⁷⁾ and was lower than Rooijens et al.⁽¹⁶⁾ and Dereli et al.⁽¹⁸⁾ who had reported 10% and 4.34% respectively. Single case (7.7%) developed 0.5cm pseudoaneurysm 3 months following construction of the BBAVF and remained at the same size throughout the follow up period. The small size of the aneurysm didn't warrant active management. This incidence was higher than reported by Sande et al.⁽¹⁵⁾ 4.9% and also higher than Keuter et al.⁽¹⁷⁾ who reported single case, out of 31 cases, developed pseudoaneurysm (3.2%) which necessitated surgical intervention. Again, our small sample size may be responsible for our higher incidence of pseudoaneurysm than that reported by Keuter et al.⁽¹⁷⁾.

The overall infection rate among our both groups was low. One diabetic patient (9.1%) in the forearm loop group had infection at the transverse segment of the loop 2 months following conservative management of seroma developed at the same site. This infection progressed to abscess formation. Abscess was managed by limited surgical incision followed by antibiotics according to culture and sensitivity. Unfortunately, this patient developed another episode of infection but this time at the site of the anastomosis and necessitated ligation and extirpation of the graft. This was correlating with what had been reported by Sande et al.⁽¹⁵⁾ and Rooijens et al.⁽¹⁶⁾ being 15.4% and 13%, respectively, who had reported slightly higher incidence of infection than in our cases, also correlated with Dereli et al.⁽¹⁸⁾ who had reported slightly lower incidence of infection being 8.68%. On the other hand, we hadn't encountered infection among the BBAVF cases. This was correlating with the low incidence of infection that had been reported by Canbaz et al.⁽¹³⁾, Dix and khan⁽¹⁴⁾, Coburn and Carney⁽¹⁹⁾ and Keuter

et al.⁽¹⁷⁾ being 4.7%, 3.6%, 3.4%, and 2.4%, respectively. Murphy et al. reported 15% infection rate⁽¹²⁾. This higher incidence of infection represented accumulation of cases along longer period of follow up (3years) versus 1 year follow up in our series.

Bleeding can present by a hematoma, that can be treated conservatively, or by bleeding that requires wound exploration and evacuation. One patient in the forearm loop group developed significant bleeding 4 hours postoperatively needed exploration. A slipped ligature from a tributary of the basilic vein was found to be the cause of bleeding. Dereli et al.⁽¹⁸⁾ reported a slightly lower incidence (8.68%) of bleeding than ours. In our study we didn't report bleeding among the BBAVF cases. Dix and khan⁽¹⁴⁾ and Coburn and Carney⁽¹⁹⁾ had reported slightly higher incidence of bleeding being (3.8%, 6.8%) within the same follow up period.

After six months of follow up of the BBAVF group cases, the primary patency and assisted primary patency rates were 92.3% and 100%, respectively as there was one patient in the BBAVF group who developed 70% stenosis in the transposed basilic vein and underwent successful PTA. While by the end of the first year follow up of the same group we had primary and assisted primary patency rates 84.6% and 100%, respectively and this was attributed to another patient who was developed stenosis in the transposed basilic vein and managed successfully with PTA without stenting. The primary patency rate among the BBAVF cases was correlating with Coburn and Carney⁽¹⁹⁾, Dix and khan⁽¹⁴⁾, Murphy et al.⁽¹²⁾ and Canbaz et al.⁽¹³⁾ who had reported primary patency 90%, 72%, 73% and 77%, respectively. Our assisted primary patency was correlated with Sande et al.⁽¹⁵⁾ who had reported slightly lower incidence of 83%.

In the forearm loop group, our primary patency rate after one year was 81.8% and this was correlated with what had reported by Georgiadis et al.⁽¹¹⁾ and Dereli et al.⁽¹⁸⁾ being 93% and 86%, respectively, it was higher than what had reported by Rooijens et al.⁽¹⁶⁾ and Dammers et al.⁽¹⁰⁾ being 43% and 44%, respectively.

CONCLUSION

Inspite that the Limitations of our study was the relatively short follow-up time and small sample size, but in the light of the data reviewed here, there was no significant difference in the postoperative complications in both groups except for the oedema that was higher and took longer time in the loop group compared to the BBAVF group. The 24 patients that were followed up for one year, 22 patients had a successful dialysis throughout the follow up period with only one patient from the loop group that developed thrombosis, and another patient had to have his fistula ligated due to uncontrolled infection. This encourages us to recommend the forearm loop synthetic graft as a prior option to the BBAVF, with early maturation and dialysis, long segment for puncture and accepted complications compared to the BBAVF, this would save the patient precious time and reserve the precious arm veins as an alternative access in case of failed loop graft.

The concept of "Whenever BBAVFs fail, it is still possible to create a prosthetic graft fistula in most patients"⁽²⁰⁾ has to be changed to become "Whenever loop forearm prosthetic graft fails, it is still possible to have a BBAVF".

REFERENCES

1. ESRD Patients in 2013 A Global Perspective...F00005993 GB (2 PUR-Burg 04.14) © Copyright 2014 Fresenius Medical Care Deutschland GmbH.
2. Allon M, Robbin ML. Increasing arteriovenous fistulas in hemodialysis patients: problems and solutions. *Kidney Int* 2002; 62: 1109–1124.
3. Santoro, A., et al., Vascular access for hemodialysis. *J Nephrol*, 2006. 19(3): p. 259-64.
4. Hallett JW, Mills JL, Earnshaw JJ, et al. Hemodialysis access placement and management of complications. *Comprehensive Vascular and endovascular surgery* 2009; 26: 430-456.
5. Besarab A, Work J, Brouwer D, Bunchman TE, Dinwiddie LC, Goldstein SL, et al. Clinical practice guidelines for vascular access. *Am J Kidney Dis* 2006;48(Suppl 1):S176-247.

6. Tordoir JH, Mickley V. European guidelines for vascular access: clinical algorithms on vascular access for hemodialysis. *Edtna Erca J* 2003;29: 131-6.
 7. Shen, D., Paper PO06 Randomization in Clinical Trial Studies, 2006.
 8. Korkut AK, Kosem M. Superficialization of the basilic vein technique in brachio-basilic arteriovenous fistula: surgical experience of 350 cases during 4 years period. *Ann Vasc Surg*. 2010 Aug;24(6):762-7.
 9. U.S. Renal Data System. *USRDS 2013 Annual Data Report: Atlas of End-Stage Renal Disease in the United States*, National Institutes of Health, National Institute of Diabetes and Digestive and Kidney Diseases, Bethesda, MD, 2014.
 10. Dammers R, Tordoir JH, Kooman JP et al. The effect of flow changes on the arterial system proximal to an arteriovenous fistula for hemodialysis. *Ultrasound Med Biol* 2005; 31: 1327–1333.
 11. Georgiadis, G.S. et al., Comparison of standard forearm prosthetic loop grafts to composite semiloop forearm grafts (— semi-grafts) in hemodialysis patients: A prospective study. , pp.1–10, 2016.
 12. Murphy, G.J. et al. Long-term results of arteriovenous fistulas using transposed autologous basilic vein. , pp.819–823, 2000.
 13. Canbaz, S. et al., Basilic vein superficialization for hemodialysis vascular access., 21(4), pp.950–954, 2013.
 14. Dix, F.P. & Khan, Y., The Brachial Artery-basilic Vein Arterio-venous Fistula in Vascular Access for Haemodialysis — A Review Paper. , 79, pp.70–79, 2006.
 15. Sande, F.M. Van Der, Welten, J.T.J. & Tordoir, J.H.M., A randomized multicenter study of the outcome of brachial-basilic arteriovenous fistula and prosthetic brachial-antecubital forearm loop as vascular access for hemodialysis. , pp.395–401, 2003.
 16. Rooijens, P.P.G.M. et al., Autogenous radial-cephalic or prosthetic brachial-antecubital forearm loop AVF in patients with compromised vessels? A randomized, multicenter study of the patency of primary hemodialysis access. , pp.481–487, 2005.
 17. Keuter, X.H.A. et al., Excellent performance of one-stage brachial – basilic arteriovenous fistula. , (July), pp.2168–2171, 2005.
 18. Dereli, Y. et al., Early and mid term results of with loop PTFE graft for hemodialysis original article hemodializ. *AMAÇLI*, 6(21), pp.485–490, 2012.
 19. Coburn MC, Carney WI. Comparison of basilic vein and polytetrafluoroethylene for brachial arteriovenous fistula. *J Vasc Surg* 1994; 20:896–904.
 20. Matsuura JH, Rosenthal D, Clark M, Shuler FW, Kirby L, Shotwell M, et al. Transposed basilic vein versus polytetrafluoroethylene for brachialaxillary arteriovenous fistulas. *Am J Surg* 1998;176:219-21.
-