

Idiopathic Granulomatous Mastitis: Is A Challenging Disease

Ayman M. A. Ali MD. & Ahmed Gaber Mahmoud MD.

General Surgery Department, Sohag Faculty of Medicine, Egypt

ABSTRACT

Idiopathic granulomatous mastitis (IGM) is a rare benign disease of uncertain etiology having diagnostic and therapeutic challenges which was treated surgically with poor outcome. This study tried to clarify the diagnostic difficulties and to evaluate different lines of treatment and their outcomes. This is a prospective descriptive study included 9 patients with proven IGM based on clinical, radiological and pathological examinations. The outcome of different treatment options was evaluated after a mean follow-up period of 18.9±2.1 months. All patients presented with a history of a unilateral painful palpable breast lump. Patients had a clinical presentation mimic inflammation in (56%) and malignancy in (44%). Histopathology was conclusive in exclusion of other causes of granulomas thus diagnosing IGM while ultrasonography and mammography was not. Eight patients out of nine responded to corticosteroid therapy (mean 3.5 months) while one was resistant and responded to surgical excision. At follow-up (22%) had recurrence and responded well to a second course of corticosteroid. A combination of surgery and medical treatment for Idiopathic granulomatous mastitis according to the severity is better than any alone.

Keywords: Granulomatous lobular mastitis, corticosteroid treatment, Breast Carcinoma

INTRODUCTION

Idiopathic granulomatous mastitis (IGM) is a rare chronic, noncaseating, granulomatous lobulitis of uncertain etiology first described in 1972;¹ only a few hundred patients have been reported worldwide,² representing a challenge to diagnose, manage and avoid iatrogenic complications, so requires multidisciplinary approach. While granulomatous breast disease may be secondary to a systemic disease such as Wegener's granulomatosis,³ sarcoidosis, diabetes mellitus, or connective tissue disorders, IGM describes granulomatous lesions without a cause; its diagnosis is made only by exclusion through serological tests and histological study.

It is more common in women of childbearing age, taking oral contraceptives or close to a period of childbirth or breastfeeding, thus suggesting hormonal influence. It may be associated with autoimmune disorders, alpha-1 antitrypsin deficiency and hyperprolactinemia⁴ suggesting an autoimmune etiology, also mammary duct ectasia is considered as another risk factor.^{5,6,7}

IGM is usually unilateral,⁶ while bilateral cases are present in up to 25% of patients.⁵ It presents in 2 forms; either as a painful breast lump which simulate cancer or as recurrent inflammatory breast lumps of varying sizes that may require open drainage in about half of the patients, skin ulcerations, and fistulae; in such

patients biopsies from the abscess wall are helpful in the diagnosis.^{4,8,9} In practice, there is no clear pattern of clinical, mammographic or ultrasound findings and biopsies are needed for diagnosis¹⁰ to exclude other causes of granulomas and show noncaseating granulomatous lobulitis.

Treatment includes corticosteroids,¹¹ immunosuppressants,¹² and sometimes colchicine⁹ allowing more conservative surgery. In patients with delayed wound healing a short therapy of high-dose steroids can be efficient.¹³ In the other hand surgical treatment may be needed for the resistant cases.¹⁴ There may be fallacies in the form of overtreatment as a breast cancer resulting in unnecessary mastectomies.¹⁵ IGM is a self-limiting condition,⁵ regardless of treatment approach, the condition takes 6 to 12 months to resolve^{16,17} but a chronic presentation could last for several years¹⁸ so, patient's understanding is very important to minimize psychological trauma.⁴ Women often get depressed due to chronic nature of disease and recurrences and may need antidepressants as adjuvants.¹⁹ A long-term monitoring is indicated since the condition recurs in 25% of all patients.²⁰

Aim of the work:

The aim of this work was to clarify the diagnostic difficulties and evaluation of management of IGM with either nonsurgical or surgical treatment and their outcomes.

PATIENTS AND METHODS

This was a prospective descriptive clinical study performed from January 2008 to December 2013 including 9 female patients presented to Sohag University Hospital with painful breast lump associated with or without minimal signs of infection, those with recurrent breast abscesses after drainage and full course of antibiotics, non responsive breast abscess to antibiotics with persistent lumps after drainage especially those acquired mammary duct fistulae with a pus-like discharge, with negative bacterial, fungal and tuberculosis (T.B.) cultures and stains and proven by histopathologic diagnosis to be IGM by either incisional biopsy from the residual lump or wall of drained abscess or by Tru-cut needle biopsy from breast lump.

Exclusion criteria included a current or previous history of breast cancer or breast radiation therapy and breast surgery within the past 12 months, postradiotherapy abscess formation, those who had history of cosmetic treatment by injection of silicone, liquid paraffin, or beeswax into the breast parenchyma (olegranulomatous mastitis) and those who lost follow-up.

All patients underwent clinical breast examination to identify palpable lumps, signs of inflammation, mobility, and axillary lymphadenopathy. The findings were confirmed by ultrasonography, mammography and histopathology. Serum prolactin levels were also estimated.

The treatment strategies were tailored as non surgical treatment in the form of amoxicillin and clavulanate empirically for 14 days in patients presented with inflammatory findings, and corticosteroid therapy in all patients in the form of oral methyl-prednisone prescribed at a dose of 0.8 mg/kg/day and continued until the symptoms were completely resolved even if ultrasonography showed residual IGM lesions, the steroid therapy was terminated by reduction 0.1 mg/kg weekly if the IGM became smaller and did not cause pain. A second course of steroid therapy was also prescribed for recurrent cases. Calcium intake to at least 1500 mg of calcium was supplemented together with 400 IU vitamin D daily in addition to H₂ blocker daily to guard against peptic ulceration. Surgical treatment in the form of incision and drainage of an abscess with biopsy in patients with subcutaneous collection and surgical excision was performed for patients with

persistant lump after steroid therapy and in resistant patients to steroid therapy.

The mean follow-up duration after treatment was 18.9±2.1 months by monthly clinical examination and imaging for the primary outcome measures; morbidity and recurrence of the disease till resolution of the symptoms then every three months.

Variables studied included age, side and location of the lesion, history of smoking, taking contraceptive pills, parity, pregnancy and lactation, type of treatment, recurrence, and clinical features included complications of breast abscess e.g. mammary duct fistulae were also recorded. The collected data were then evaluated by SPSS 18 in the form of percentages and mean values.

RESULTS

This study included 9 female patients with IGM, after exclusion of 2 patients lost follow-up. The patients' age ranged from 23-38 (mean=35) years, with a parity ranged from 2-5 (mean=3). All were regularly breast fed their babies and were post-lactation by 3 months to two years. They had received T.B. vaccination while they were children and were weak tuberculin positive in 4 patients (44%) and negative in 5 patients (56%) prior to treatment. None of the patients had a history of galactorrhea, any systemic disorder or history of a specific infection. They were nonsmokers except one, none were on any medication or hormonal treatment at diagnosis and seven patients (78%) had history of taking contraceptive pills (Table 1).

All patients diagnosed as IGM presented with a painful palpable unilateral breast lump, in the outer quadrants in five patients (56%) and retroareolar in the rest of patients (44%), its size ranged from 5-10 (mean=6.5) cm and duration of symptoms was 1-4 (mean=2.5) months. The right breast was involved in 6 patients (67%) and the left one was involved in 3 patients (33%). They had the clinical presentation of inflammation in 5 patients (56%), with persistent mammary duct fistulae in 3 of them, and the other 4 women (44%) had a malignancy like presentation. Axillary lymphadenopathy was present in 2 patients (22%) (Table 1 & Figure 1).

Ultrasonography examination showed an irregular hypoechoic mass with multiple tubular extensions and posterior shadowing in 4 patients (44%), a lobulated or irregular mass was seen in 3 women (33%) and no discrete mass in 2 women

(22%), and axillary lymphadenopathy in 4 patients (44%). Mammography was conducted in 5 patients (56%) and showed a heterogeneously dense parenchymal breast pattern; in addition three patients (60%) of them had a large focal asymmetric density (Table 1, Figures 2, 3 & 4).

Three sputum smears were negative for T.B., polymerase chain reactions (PCR) were negative and chest radiographs were normal for all.

Histopathologic diagnosis in patients mimic carcinoma (4 patients) was by Tru-cut needle biopsy in 3 of 4 patients (75%) and by incisional biopsy in the remaining one (25%) and in those mimic inflammation diagnosis was made by Tru-cut needle biopsy in 2 of 5 patients (40%) and by incisional biopsy in 3 of 5 patients (60%). Microscopically, there were areas of necrosis and acute and chronic inflammatory cells with foamy macrophages, epithelioid cells, and multinucleated giant cells forming granulomas. There were no caseations, no malignant cells, fungi, or acid-fast bacilli (Table 2).

Five women (56%) had already been treated by a course of antibiotics with additional incision and drainage in 3 patients (33%) of them with negative culture and sensitivity. Steroids were prescribed for 9 women, the mean dosage was 45 mg/day (range: 40–60 mg/day; mean weight was

65 kg). All patients received corticosteroid were improved except one which was subjected furtherly to surgical excision. Complications due to steroid therapy were observed in one patient who got a temporary steroid-induced diabetes mellitus. Surgical treatment was conducted in 5 women (55%) in the form of incision and drainage in 3 patients (33%) and wide surgical excision in 3 patients (33%) including one previously treated with incision and drainage. So the received treatment was no treatment (0), antibiotics alone (0), steroids alone (2), surgery alone (0), antibiotics and steroids (2), antibiotics and surgery (0), antibiotics and steroids with additional incision and drainage (3), steroids and excisional surgery (2), and lastly antibiotics and steroids with additional excisional surgery (1) (Table 2).

At follow-up complete response varied from 2-5 (mean 3.5) months and 2 patients (22%) had recurrent disease; they were treated by a second course of corticosteroids. Recurrence developed 7 months or more after completion of steroid therapy. Patients who had mammary duct fistulae and microabscess formation needed more time to heal. There were only two of 11 patients lost to follow-up (Table 3).

Table 1. Preoperative characteristics, clinical presentation, and investigations

	Number	Value
Patients received T.B. vaccination	9	100%
Tuberculin test		
• weak positive	4	44%
• Negative	5	56%
Patients had systemic disorder or history of a specific infection	0	0
Patients on contraceptive pills	7	78%
History of smoking	1	11%
History of regular breast feeding	9	100%
Clinical presentation		
• Unilateral painful breast lump	9	100
• Site		
Outer quadrants	5	56%
Retroareolar region	4	44%
• Side		
Right	6	67%
Left	3	33%
• inflammatory changes	5	56%
• Mammary duct fistulae	3	33%
• Mimic malignant breast lump	4	44%
• Axillary lymphadenopathy	2	22%
Ultrasound examination		
• Irregular mass with posterior acoustic shadowing	4	44%
• Lobulated or irregular mass	3	33%
• No mass	2	22%
• Axillary lymphadenopathy	4	44%
Mammography		
• Heterogeneous dense parenchymal breast pattern	5 (of 5)	100%
• Large focal asymmetric density in addition	3 (of 5)	60%

Table 2. Diagnosis and treatment

<i>Clinical Presentation</i>	<i>Frequency</i>	<i>Diagnosis</i>	<i>Received treatment</i>
Carcinoma like	4 (of 9)	Tru- cut 3 (of 4) Incisional biopsy (1 of 4)	<ul style="list-style-type: none"> • Steroids alone 2 (of 4) • Steroids plus wide resection 2 (of 4)
Inflammation like	5 (of 9)	Tru- cut 2 (of 5) Incisional biopsy 3 (of 5)	<ul style="list-style-type: none"> • Antibiotics plus steroids 2 (of 5) • Antibiotics plus steroids with incision and drainage 3 (of 5) • 3 (of 5) • Antibiotics plus steroids with wide resection 1 (of 3)**

Table 3. Treatment and response

<i>Clinical Presentation</i>	<i>Frequency</i>	<i>Received treatment</i>	<i>Response</i>		
			Improvement	Failure	Recurrence
Carcinoma like	4 (of 9)	• Steroids alone 2 (of 4)	2 (of 2)	Nil	Nil
		• Steroids plus wide resection 2 (of 4)	2 (of 2)	Nil	Nil
Inflammation like	5 (of 9)	• Antibiotics plus steroids 2 (of 5)	2 (of 2)	Nil	1 (of 2)
		• Antibiotics plus steroids with incision and drainage 3 (of 5)	2 (of 3)	1 (of 3)**	1 (of 3)
		• Antibiotics plus steroids with wide resection 1 (of 3)**	1 (of 1)	Nil	Nil

**The case managed with antibiotics plus steroids with wide resection is the one which was refractory to antibiotics plus steroids with incision and drainage

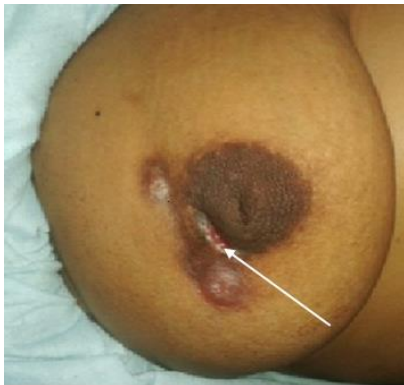

Figure 1. Right breast of an IGM patient before treatment, showing multiple mammary duct fistulae and non-healing wound (skin ulceration) after drainage of an abscess (white arrow). Informed consent was obtained from the patient to print this photograph.

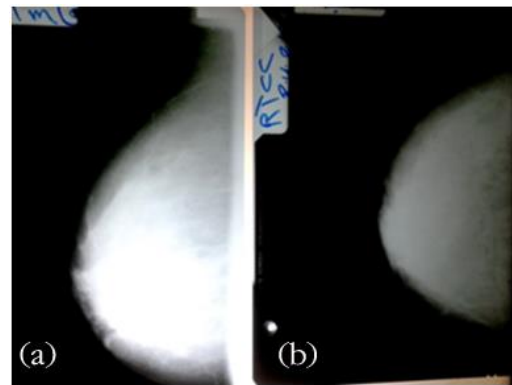


Figure 2. Mammography of the right breast with IGM; a: right lateral-medial oblique, b: right craniocaudal view revealed an irregular, indistinct high density mass with poorly defined margins in the retroareolar region with retraction of the nipple, but without focal microcalcification.

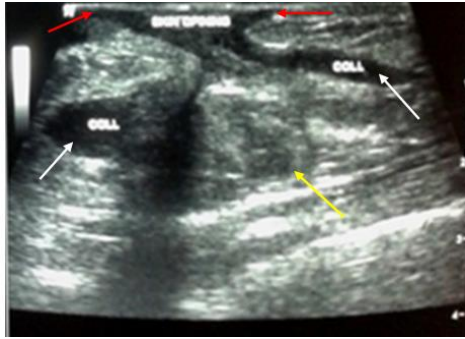


Figure 3. Breast ultrasonography of right breast with IGM demonstrates an ill-defined, irregular lesion of mixed echogenicity (yellow arrow), hypoechoic mass lesions of subcutaneous collections (white arrows) which corresponds to multiple subcutaneous abscesses that open into the skin with mammary duct fistulae (red arrows).

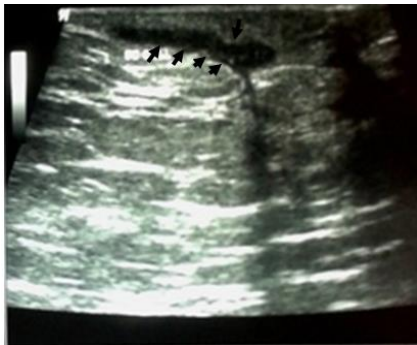

Figure 4. Breast ultrasonography shows an ill-defined, irregular tubular, hypoechoic lesion (black arrows), consistent with IGM.

DISCUSSION

IGM is a rare chronic benign breast disease presenting a dilemma in its etiology, diagnosis and treatment; even it can turn malignant.²¹ The mean age of our patients was 35 years, which was comparable to that in previous studies.^{22,23} There is an increased frequency of IGM reported patients from the developing countries^{24,25,26} which have been postulated as underdiagnosis of T.B. mastitis.¹³ This may lead to mismanagement of IGM as T.B., two patients of our series received antituberculous treatment for 3 months without investigatory proof nor response. So it is better to suggest this increased frequency as an unknown etiology, or increased awareness with the disease.

There was no association observed between IGM and smoking as all the studied patients were non smokers except one, contrary to periductal mastitis.²⁷ Trauma to the breast, foreign material, pregnancy, breast-feeding, and oral contraception, all had been postulated but never proven risk factors.^{6,24} So, a localized autoimmune mechanism to extravasated lactational secretions secondary to damage to ductal epithelium was postulated as an etiology,^{10,28} also IGM often improves with administration of steroids. In addition erythema nodosum and Sjögren's syndrome, has been noticed as an extramammary manifestations of IGM.^{29,30} On the other hand, serologic tests of autoimmune disorders, such as antinuclear antibodies and rheumatoid factors, are usually found to be negative.²⁴

All of our patients were presented with a tender unilateral breast lump associated with fixation to the skin or to the underlying muscle in a post-lactating women without predilection to any side, this comes in accordance to the others,³¹ although bilateral cases has been described.³² As IGM predominantly occurs in nonlactating women,^{33,34} it is assumed to be malignant^{7,33,35} rather than inflammatory one. IGM must be considered as a rare differential diagnosis.³⁶ Regional lymphadenopathy; which may be mistaken for malignancy was present in 22% of our patients, a figure more or less recorded by the others.³⁷ If after 10 days of antibiotic therapy symptoms of mastitis do not disappear, punch skin biopsy should be performed to exclude inflammatory carcinoma.³⁸

Preoperative diagnosis of IGM should be accomplished to decide the best therapeutic strategy. This is based on the characteristic histopathological pattern. As there are no radiologic pathognomonic findings specific for IGM either by mammography or ultrasonography even they may increase the dilemma of diagnosis by findings similar to malignancy or even abscess.³⁹ As IGM may be mistaken for inflammatory lesions, it is usually treated as such without biopsy which delays the diagnosis and makes presentation late and complicated. So when mastitis persists after medical treatment biopsy is mandatory.⁴⁰ In this study, the diagnosis was made by histopathological examination excluding other granulomatous inflammations through identification of granulomatous inflammation centered on lobules (granulomatous lobulitis) with

absence of caseating necrosis.⁴¹ We excluded patients who had previous surgical procedures as in these patients difficult for pathologists to differentiate between true IGM and periductal mastitis.⁴²

There is no agreement regarding the best treatment of IGM, treatment options include waiting policy with spontaneous remission, corticosteroid therapy, immunosuppressive agents and extensive surgery for resistant cases.⁴¹ An initial treatment option for patients with new-onset IGM, with mild to moderate symptoms may be expectant policy with close regular follow-up. For those with clinically advanced disease or more severe symptoms, in whom infectious etiologies have been excluded, oral prednisone till clinical improvement is recommended as there is a 50% chance of relapse.⁴³ Treatment of IGM with steroids before surgical management is beneficial, with 77% of patients showing improvement.¹⁰ Also it is associated with a significant decrease in the number of recurrences compared with that before treatment,⁴⁴ provides significant regression of the inflammatory symptoms and effective for shrinking the granulomatous lump thus allowing more conservative surgical excision of the remaining lesions after medical treatment; because most involved patients have large, diffuse, or multiple lesions, the surgical treatment is mutilative and should be taken seriously as a first line for treatment.^{28,45,46}

The use of corticosteroid therapy alone is associated with recurrence reaching up to 50%.²² Also with limited excision alone recurrence rate approaches 50% which necessitates extensive resection to obtain disease-free margins besides other surgical complications,⁴⁷ which when treated by re-excision only is associated with recurrence after surgery of (23%).²⁰ Therefore excision of the recurrence alone is inadequate treatment and additional therapy may be indicated.⁴⁸ Our adopted therapeutic strategy was to start with corticosteroid alone or in combination with antibiotics while surgery is kept for patients with collection, those which became shrunken but did not disappear after medical treatment and resistant cases. In our study we got 89% improvement with steroids alone or combined to antibiotics and surgery which makes steroid therapy the first choice for IGM patients keeping surgical excision as a second line for

resistant cases.¹⁴ The resistance to steroids can be explained by categorization of IGM as immunoglobulin G (IgG) 4-related IGM and non-IgG4-related IGM.⁴⁹ We got (22%) recurrence rate which developed 7 months after completion of the first course of steroid therapy suggesting more the autoimmune nature of the disease. Also from these results, it is clear that recurrence after wide surgical excision next to steroid therapy is nil as radical excision is warranted by preoperative corticosteroids to minimize resection. Hence, long term follow-up is recommended.

In conclusion IGM needs a multi-disciplinary approach for diagnosis and treatment; which should be tailored for every patient according to the severity to achieve a better cosmetic result and a lower recurrence rate.

REFERENCES

1. **Kessler E, Wolloch Y.** Granulomatous mastitis: a lesion clinically simulating carcinoma. *Am J ClinPathol.* 1972;58:624-46.
2. **Wilson JP, Massoll N, Marshall J, Foss RM, Copeland EM, Grobmyer SR.** Idiopathic granulomatous mastitis: in search of a therapeutic paradigm. *Am Surg.* 2007;73:798-802.
3. **Veerysami M, Freeth M, Carmichael AM, et al.** Wegener's granulomatosis of the breast. *Breast J.* 2006;12:268-70.
4. **Lai ECH, Chan WCH, Ma TKF, Tang APY, Poon CSP, Leong HT.** The role of conservative treatment in idiopathic granulomaotus mastitis. *Breast J.* 2005;6:454-6.
5. **Erzogen F, Ersoy YE, Akaydin M.** Corticosteroid treatment and timing of surgery in idiopathic granulomatous mastitis confusing with breast carcinoma. *Breast Cancer Res Treat.* 2010;123:447-52.
6. **Vinayagam R, Cox J, Webb L.** Granulomatous mastitis: a spectrum of disease. *Breast Care.* 2009;4:251-4.
7. **Going JJ, Anderson TJ, Wilkinson S, et al.** Granulomatous lobular mastitis. *J Clin Pathol.* 1987;40:535-40.
8. **Konan A, Kalyoncu U, Dogan I, Kılıc YA, Karakoc D, Akdogan A, Kiraz S, Kaynaroglu V, Onat D.** Combined long-

- term steroid and immunosuppressive treatment regimen in granulomatous mastitis. *Breast Care*. 2012;7:297-301.
9. **Diesing D, Axt-Flidner R, Hornung D, Weiss JM, Diedrich K, Friedrich M.** Granulomatous mastitis. Review article. *Arch Gynecol Obstet*. 2004;269(Suppl 4):233-6.
 10. **Larsen L.J.H., Peyvandi B, Klipfel N, Grant E, Iyengar G.** Granulomatous lobular mastitis: imaging, diagnosis, and treatment. *AJR*. 2009;193:574-81.
 11. **DeHertogh DA, Rossof AH, Harris AA, Economou SG.** Prednisone management of granulomatous mastitis. *N Engl J Med*. 1980;303:799-800.
 12. **Akbulut S, Yilmaz D, Bakir S.** Methotrexate in the management of idiopathic granulomatous mastitis: review of 108 published cases and report of four cases. *Breast J*. 2011;17:661-8.
 13. **Bani-Hani K. E., Yaghan R. J., Matalka I. I., and Shatnawi N. J.** Idiopathic granulomatous mastitis: time to avoid unnecessary mastectomies. *Breast J*. 2004;10:318-22.
 14. **Akahane K, Tsunoda N, Kato M, Noda S, Shimoyama Y, Ishigaki S, Satake H, Nakamura S and Nagino M.** Therapeutic strategy for granulomatous lobular mastitis: a clinicopathological study of 12 patients. *Nagoya J. Med. Sci*. 2013;75:193-200.
 15. **Imoto S, Kitaya T, Kodama T, Hasebe T, Mukai K.** Idiopathic granulomatous mastitis: case report and review of the Literature. *Jpn J ClinOncol*. 1997;27:274-7.
 16. **Amir M.** Idiopathic granulomatous mastitis - a diagnostic and therapeutic dilemma. *Rawal Medical Journal*. 2013;38:90-1.
 17. **Al-Khaffaf B, Knox F, Bundred NJ.** Idiopathic granulomatous mastitis: a 25-year experience. *J Am Coll Surg*. 2008;206(Suppl 2):269-73.
 18. **Garcia-Rodriguez JA and Pattullo A.** Idiopathic granulomatous mastitis: a mimicking disease in a pregnant woman: a case report. *BMC Research Notes*. 2013;6:95-8.
 19. **Bellavia M, Damiano G, Palumbo VD, Spinelli G, Tomasello G, Marrazzo A, et al.** Granulomatous Mastitis during Chronic Antidepressant Therapy: Is It Possible a Conservative Therapeutic Approach? *J Breast Cancer*. 2012;15:371-2.
 20. **Kok KYY, Telisinghe PU.** Granulomatous mastitis: presentation, treatment and outcome in 43 patients. *The surgeon*. 2010;8:197-201.
 21. **Kocaoglu M, Somuncu I, Ors F, Bulakbasi N, Tayfun C, et al.** Imaging findings in idiopathic granulomatous mastitis. A review with emphasis on magnetic resonance imaging. *J Comput Assist Tomogr*. 2004;28:635-41.
 22. **Azlina AF, Ariza Z, Arni T, Hisham AN.** Chronic glaucomatous mastitis: diagnostic and therapeutic considerations. *World J Surg*. 2003;27:515-8.
 23. **Ocal K, Dag A, Turkmenoglu O, Kara T, Seyit H, et al.** Granulomatous mastitis: clinical, pathological features, and management. *Breast J*. 2010;16:176-82.
 24. **Akcan A, Akyildiz H, Ali Deneme M, Akgun H, Aritas Y.** Granulomatous lobular mastitis: a complex diagnostic and therapeutic problem. *World J Surg*. 2006;30:1403-9.
 25. **Asogolu O, Ozmen V, Karanlik H, Tunaci M, Cabioglu N, Igci A, Selcuk UE and Keceer M.** Feasibility of surgical management in patients with granulomatous mastitis. *Breast J*. 2005;11:108-14.
 26. **Ozturk M, Mavili E, Kahrman G, et al.** Granulomatous mastitis: radiological findings. *ActaRadiologica*. 2007;48:150-5.
 27. **Gollapalli V, Liao J, Dudakovic A, Sugg SL, Conner CEHS, Weigel RJ.** Risk factors for development and recurrence of primary breast abscesses. *J Am Coll Surg*. 2010;211:41-8.
 28. **Yau FM, Macadam SA, Kuusk U, Nimmo M, Van Laeken N.** The surgical management of granulomatous mastitis. *Ann Plast Surg*. 2010;64:9-16.
 29. **Letourneux C, Diemunsch P, Korganow AS, Akladios CY, Bellocq JP and Mathelin C.** First report of granulomatous mastitis associated with Sjögren's syndrome. *World Journal of Surgical Oncology*. 2013;11:268-72.
 30. **Bes C, Soy M, Vardi S, Sengul N, Yilmaz F.** Erythema nodosum associated with granulomatous mastitis: report of two cases. *Rheumatology International*. 2010;30:1523-5.
-

31. **Jorgensen MB, Nielsen DM.** Diagnosis and treatment of granulomatous mastitis. *Am J Med.* 1992;93:97-101.
 32. **Orsaria P, De Sanctis F, Esser A, Dori L, Bonanno E, Petrella G, Buonomo O.** Bilateral involvement in patients with granulomatous mastitis: Surgical treatment and case report. *Case Reports in Clinical Medicine.* 2013;525-9.
 33. **Howell JD, Barker F, Gazet JC.** Granulomatous lobular mastitis: report of a further two cases and a comprehensive literature review. *Breast J.* 1994;3:119.
 34. **Disease of Breast, 2nd ed. Edited by Jay R.** Harris Lippincott Williams & Wilkins, Philadelphia. 2000;4:54.
 35. **Dixon JM, Breast Infection.** ABC of breast diseases. *BMJ.* 1994;309:946-9.
 36. **Fard FE, Beygi AN, Kavyani A, Jalali AH.** Idiopathic granulomatous mastitis: report of 3 cases and a review of the literature. *Medical Journal of the Islamic Republic of Iran.* 2010;23: 233-7.
 37. **Fletcher A, Magrath IM, R'ddell RH, et al.** Granulomatous mastitis: a report of seven cases. *J ClinPathol.* 1982;35:941-5.
 38. **Kamal RM, Hamed ST, Salem DS.** Classification of inflammatory breast disorders and step by step diagnosis. *Breast J.* 2009;15:367-80.
 39. **Gautier N, Lalondea L, Tran-Thanhc D, El Khourya M, Davida J, Labellea M, Patocskaid E, Tropa I.** Chronic granulomatous mastitis: Imaging, pathology and management. *European Journal of Radiology.* 2013;82:e165–e175.
 40. **Mansour S.M., Abolfotooh A.** Does MRI help in the assessment of inflammatory breast disorders? *The Egyptian Journal of Radiology and Nuclear Medicine.* 2012;43:487-97.
 41. **Tuli R, O'Hara BJ, Hines J, Rosenberg AL.** Idiopathic granulomatous mastitis masquerading as carcinoma of the breast: a case report and review of the literature. *Int Semin Surg Oncol.* 2007;4:21.
 42. **Lester SC.** Differential diagnosis of granulomatous mastitis. *Breast J.* 2005;11:534-5.
 43. **Varshochi M, Haghdoost M and Mashrabi O.** Idiopathic Granulomatous Mastitis: A Case Report. *American Journal of Infectious Diseases.* 2010;6:61-5.
 44. **Hugon-Rodin J, Plu-Bureau G, Hugol D, Gompel A.** Management of granulomatous mastitis: a series of 14 patients. *GynecolEndocrinol.* 2012;28:921-4.
 45. **Gurleyik G, Aktekin A, Aker F, Karagulle H, Abdullah Saglam A.** Medical and surgical treatment of idiopathic granulomatous lobular mastitis: a benign inflammatory disease mimicking invasive carcinoma. *J Breast Cancer.* 2012;15:119-23.
 46. **Sakurai K, Fujisaki S, Enomoto K, Amano S, Sugitani M.** Evaluation of follow-up strategies for corticosteroid therapy of idiopathic granulomatous mastitis. *Surg Today.* 2011;41:333-7.
 47. **Binesh F, Kargar S, Zahir ST, Behniafard N, Navabi H and Arefanian S.** Idiopathic granulomatous mastitis, a clinicopathological review of 22 cases. *J Clin Exp Pathol.* 2014;4:157-60.
 48. **Mak SK, Wong PK, Lee DWH and Chan ACW.** Granulomatous Mastitis. *Ann Coll Surg.* 2001;5:129-31.
 49. **Ogura K, Matsumoto T, Aoki Y, Kitabatake T, Fujisawa M, Kojima K.** IgG4-related tumor-forming mastitis with histological appearances of granulomatous lobular mastitis: comparison with other types of tumor-forming mastitis. *Histopathology.* 2010;57:39-45.
-