

Rectal Cancer

Haitham Akram Saimeh

Colorectal Surgery, King Faisal Specialist Hospital and Research center

ABSTRACT

Recurrence of rectal cancer represents a major challenge which greatly reduces the long-term survival, therefore intensive follow up postoperatively including both clinical and pathological findings greatly improves the overall five-year survival rate of rectal cancer patients.

In this case, we can see how there is high percent of recurrence in the rectal cancer surgery even after the total neoadjuvant CRTh and complete surgical excision, in the T2NO, we can notice still there is a recurrence rate. Surgical resection of rectal cancer depends mainly on clear CRM, free edges in addition to negative rectal mesenteric lymph nodes.

Keywords: Rectal Cancer, Rectal cancer Recurrence, Rectal cancer and Surgery.

INTRODUCTION

Colorectal cancer is one of the most commonly diagnosed cancer, based on previous countered statistics it results in 90% of all cancer reported cases.¹ The main treatment approach which is considered to be the cornerstone is surgical resection of the tumor and draining lymph nodes followed by colonoscopy every five years to determine the patients prognosis and minimize the risk of recurrence, because neoadjuvant therapy that includes chemotherapy, radiotherapy or both have shown to downstage the tumor, reducing the tumor burden prior to surgery.²

Recurrent rectal cancer is a serious clinical obstacle regardless the great approaches and interventions done to reduce the risk of encountering recurrence after surgical resection, yet a significant number of patients still experience recurrence. Recurrence is greatly associated with poor lifestyle as well as increased risk of morbidity and mortality. Great thanks to the continuous postoperative resection follow up screening programs that it more approachable and easier to detect any asymptomatic recurrence at an early stage, in order to reduce the risk of metastases.

Several factors such as lymphovascular invasion together with the tumor size act as determinants for encountering recurrence.

Case

A 57 years old, gentleman, who was investigated and diagnosed in, a tertiary hospital, with low rectal cancer in 2016.

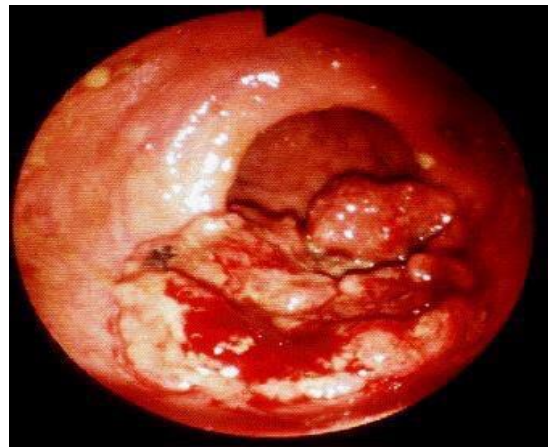


Fig 1: This figure shows the scope finding in February 2019.

Fig. 1 is a scope that was done in February 2019, pathological results showed cancer.

The patient underwent LAR without diversion, after receiving neoadjuvant CRTh pathology T2N0, free edges, no need for adjuvant CHT.

In 2019, after the first operation, LAR, pelvic MRI showed recurrent rectal cancer as indicated (**Fig. 2**).

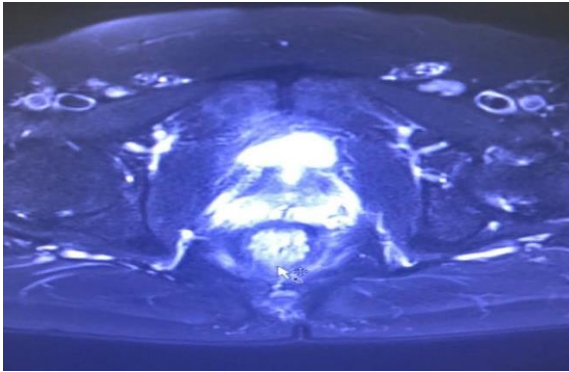


Fig 2: Pelvic MRI, indicating rectal mass recurrence.

During regular follow-up in the outpatient department, with clinical and radiological examination done routinely, results showed that there was a mass around the anus, therefore a biopsy was taken for further examination, results later indicated adenocarcinoma.

The case was discussed in the MDT and the decision was to go for abdominoperineal resection (APR).

DISCUSSION

The importance of the regular clinical follow up post rectal surgery to pick up any local, distal or regional metastases, increasing the possibility of detecting any asymptomatic recurrence that greatly reduces the patients prognosis and survival rate. In the tertiary hospital, we followed the patient as follows:

- a) U/S abdomen 3 months after the operation.
- b) Then followed up by 6 months with CT CAP.
- c) For the 5 years follow up post-surgery, it will be 6 months follow up with U/S and CT CAP alternatively.
- d) Scope, the first one will be one year post surgery and the last one after 5 years of surgery.
- e) We can do scope during the follow up, if there is any mass suspicions by radiology or clinical examination.
- f) The follow up will continue for 5 years duration in colorectal OPD.

We must place great attention on the possibility of recurrence in rectal cancer cases even after full resection of the specimen and this depends on the several factors such as Circumferential resection margin (CRM) which is considered to be most important prognostic marker together with dissection of the mesorectal fascia completely around the rectum.

Recurrence of rectal cancer occurs in several forms as distant, locally, regional and this greatly depends on many factors. One of the most important anatomical risk factors is the free margins of the distal and proximal ends. The distal end should be free, even if it is 1-2 cm or less, then we can do anastomosis and preserve the sphincters. Another vital factor is the presence of mesenteric lymph nodes metastases, solitary metastasis to the mesenteric lymph nodes is rare, however it should not be ignored.³ We also depend on lymph node positively to decide on whether doing postoperative chemotherapy or not. Not only this, but other critical factor includes circumferential resection margin (CRM) around the rectum, mesorectal complete dissection, total mesorectal excision (TME) which must totally clear and excise all around the rectum after full dissection of the rectum intraoperatively and taking out the mesorectum for pathological observation. There is a recognized decline in the incidence of experiencing recurrent rectal cancer after the introduction as well as the appropriate and correct implantation of total mesorectal excision procedure.⁴

Regarding this case the pathological report confirmed T.M.E was done completely all around the rectum, and the mesorectum contained lymph nodes if not resected completely this could raise the chance of experiencing recurrence postoperatively.

In conclusion, several prognostic examinations, together with the oncological history of the patient should be reviewed postoperative resection of rectal cancer in order to enlighten the surgeon about the patient's wellbeing postoperatively and if further surgical intervention is required or not.

REFERENCES

1. Haggard FA, Boushey RP. Colorectal cancer epidemiology: incidence, mortality, survival,

- and risk factors. *Clin Colon Rectal Surg.* 2009;22(4):191-7.
2. Feeney G, Sehgal R, Sheehan M, Kerin M, Hogan A, Regan M ., Neoadjuvant radiotherapy for rectal cancer management. *World J Gastroenterol.* 2019;25(33):4850-69.
 3. Matsuda Y, Yano M, Miyoshi N, et al. Solitary mediastinal lymph node recurrence after curative resection of colon cancer. *World J Gastrointest Surg.* 2014;6(8):164-8.
 4. Stewart DB, Dietz DW. Total mesorectal excision: what are we doing. *Clin Colon Rectal Surg.* 2007;20(3):190-202.
-