

Transanal Colonic Pull-through Procedure with Delayed Colo-anal Anastomosis in Complex Colorectal Conditions (Initial Experience)

Ahmed Morad, MD; Wael A Jumuah, MD; Hanna Habib, MD

Department of General Surgery, Faculty of Medicine,

Ain Shams University, Cairo, Egypt

ABSTRACT

Background: Transanal colonic pull-through with delayed colo-anal anastomosis (DCA) is an old surgical technique that comes back again in the last decade to avoid permanent colostomy in challenging complex colorectal conditions. In this study, we assess the feasibility, effectiveness and complications related to the procedure. **Methods:** A prospective study was conducted from September 2014 to December 2016 including 10 patients with complex colorectal conditions (6 patients had rectal cancer, 3 had massive complete rectal prolapse and one had recurrent infected rectovaginal fistula) underwent transanal colonic pull-through with DCA operation to review its feasibility and effectiveness in these situations and assessing its related morbidities and mortality. **Results:** The procedure is completed with success in 8 (80%) patients. Two (20%) patients underwent abdominoperineal resection with permanent colostomy. Two (20%) patients suffered a perineal abscess, 1 (10%) patient suffered a pelvic abscess and 1 (10%) suffered an anastomotic suture line infection. No postoperative mortality recorded. **Conclusion:** Colonic transanal pull-through with delayed colo-anal anastomosis is a feasible and effective procedure, and could be considered a salvage procedure to avoid colostomy either temporary or permanent types in complex colorectal conditions.

Key words: Colonic pull-through. Delayed colo-anal anastomosis. Rectovaginal fistula. Massive rectal prolapse. Low anterior resection

INTRODUCTION

The most important priority in the surgical management of lower rectal pathology beside adequate oncologic clearance in case of cancer is the restoration of bowel continuity^[1].

Re-anastomosis can be performed with stapler, transabdominal or transanal hand-sewn technique, or pull-through two-staged delayed colo-anal anastomosis (DCA) technique. Stapled anastomosis is now the most common method of performing the colo-anal/distal rectal anastomosis with circular stapler introduced transanally, and patients who were scheduled for abdominoperineal resection for lower rectal disease in the past, now can preserve their anal sphincter complex and avoid permanent stoma^[2,3].

But the question in cases with complicated complex colorectal conditions and after disruption of the lower colorectal or colo-anal anastomosis, or when immediate lower anastomosis couldn't be done, still can we avoid abdominoperineal resection?^[3]

In 1961, Turnbull used two stage pull-through with delayed colo-anal anastomosis in order to

avoid colostomy in Hirschsprung's disease. In 1999, Baulieux et al. reintroduced the Turnbull technique in patients with low rectal cancer receiving radiotherapy to avoid immediate anastomosis complications^[4,5,6].

So transanal colonic pull-through operation is an old surgical technique but recent literatures seem to be poor in this topic due to advances in intestinal anastomosis techniques, even many surgeons of the new generations have little knowledge about it^[7].

Introduction of neoadjuvant chemoradiotherapy in low rectal cancer increased rate of colo-anal anastomosis. The main drawback is leakage with an incidence of 2.9 – 20%^[4,8]. This incidence with its associated comorbidities mandated the need of prophylactic covering stoma, but still has its complications^[8].

Over the last 3 decades, obesity prevalence among adults has been increasing affecting 38% of the population in every country^[9]. Morbidly obese patients were found to have longer operative times than did normal patients across each individual colorectal procedure^[10], with significant association between higher body mass

index (BMI) and risk of surgical site infection and anastomotic leakage ^[11], necessitating a redo surgery with diversion.

For these reasons, transanal colonic pull-through with delayed colo-anal anastomosis comes from the past to introduce a satisfactory solution in this dilemma ^[12]. Also, it has main theoretical advantage of minimal risk anastomosis with avoidance of the need for diverting stoma in certain colorectal difficult situations and could be considered a salvage procedure ^[4, 12].

PATIENTS & METHODS

Patients:

Ten adult patients with complex challenging colorectal conditions were included in this prospective study done in Ain Shams University Hospital, from September 2014 till December 2016. The local ethical committee approved the trial and all patients gave informed consent which explained the procedure and its complications,

also, showed that the need of stoma could be an alternative option. Demographic data and operative time in each patient were recorded.

Inclusion criteria:

1. Age > 18 Ys.
2. Patients who experienced disruption of colorectal (low and very low types) or colo-anal anastomosis needing urgent intervention.
3. Intraoperative technical difficulty to achieve safe colo-anal anastomosis (e.g. high BMI patients).
4. Very high risk of leakage or disruption if colo-anal anastomosis was done due to presence of sepsis (e.g. recurrent rectovaginal fistula, ulcerated infected complete rectal prolapse).
5. At least 8 weeks interval after last neoadjuvant radiotherapy session received for rectal cancer

Exclusion criteria:

1. Presence of fecal incontinence (any grade).
2. Patients with hypotonic anal sphincter.

Table (1): Diagnosis of each patient and indication of the pull-through technique:

No	Sex	Age (Ys)	Initial diagnosis and surgery	Indication of pull-through with DCA
1	F	36	Rectovaginal fistula Failed 3 attempts of repair	Sepsis
2	M	55	Distal rectal cancer Laparoscopic low anterior resection	Misfire of stapling device BMI >45%
3	M	33	Distal rectal cancer Open low anterior resection	Anastomotic leakage with failed management trial by diverting ileostomy
4	M	48	Mid rectal cancer Laparoscopic low anterior resection	Anastomotic disruption with failed trial of management
5	F	52	Distal rectal cancer Open low anterior resection	Anastomotic disruption with failure of management
6	M	67	Mid rectal cancer Open low anterior resection	Anastomotic disruption with failure of management
7	M	44	Distal rectal cancer Laparoscopic low anterior resection	Disruption of anastomosis due to ischemia in the proximal colon end
8	F	57	Complete rectal prolapse Transanal rectosigmoidectomy with colo-anal anastomosis	Disruption of anastomosis due to colonic necrosis
9	M	63	Gangrenous irreducible complete recta prolapse Transanal rectosigmoidectomy	Sepsis and ulceration in the anal canal
10	M	67	Irreducible complete rectal prolapse Transanal rectosigmoidectomy	Inability to do immediate colo-anal anastomosis BMI 42%

Preoperative Workup:

Beside routine preoperative investigations, all patients have:

1. Digital rectal examination.
2. Colonoscopic examination and biopsy if needed.
3. Anal sphincter manometry if continence in doubt.
4. Radiologic assessment (CT or MRI) if needed.

The preoperative anesthesia evaluation was done using the American society of anesthesiology guidelines.

Surgical Technique:

Transanal colonic pull-through with delayed colo-anal anastomosis procedure was performed for all patients in 2 stages, the duration between the stages ranged between 10 & 15 days.

First stage:

The principle goal of the 1st stage was the exteriorization of the proximal colon transanally to a distance 6 -10 cm from the anal verge (fig. 1). Patients were put in lithotomy position, but the approach differed according to each case, it could be abdominoperineal or only perineal approach.

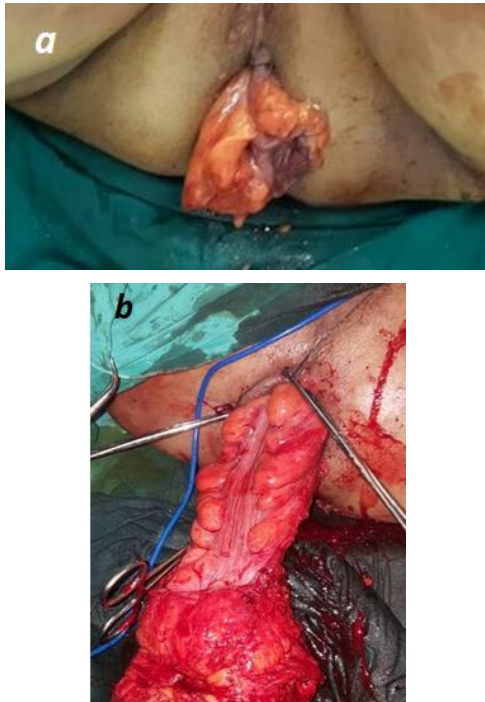


Fig. (1): Pull-through in case of recurrent rectovaginal fistula (a), and in case of massive complete rectal prolapse (b).

In patients with failure of colo-anal anastomosis due to misfire of stapler during low anterior resection of cancer rectum (fig. 2) or in case of recurrent rectovaginal fistula, the 1st stage procedure was the standard low anterior resection procedure and the distal colon was adequately mobilized to be pulled through the anus.

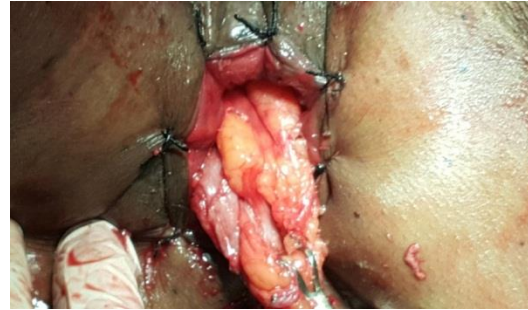


Fig. (2): A somewhat short pull-through after failed distal colorectal anastomosis due to misfire of the circular stapler

In case of failure of previous colo-anal anastomosis, the 1st stage is directed to the modified anatomy that resulted from the previous rectal surgery, if the left colon was not sufficiently long for its transposition in the pelvis, sectioning the middle colic vascular axis was done, in case if vascular supply can be ensured from the right colic vessels, it was convenient to mobilize and turn down the transverse colon to the right of small bowel, giving more length to the colon, sometimes mobilization of the whole colon, relying on perfusion coming from the ileo-colic axis, the caecum was then rotated and overturn and the proximal ascending colon was moved down to the level of the perineum.

The first stage is completely perineal in case of transanal rectosigmoidectomy for massive and irreducible complete rectal prolapse associated with failure to do immediate colo-anal anastomosis.

At the end of the 1st stage for all patients, the free end of the remaining colon was mobilized enough to allow it to reach the anal verge without tension and the neorectum was positioned down to the pelvic floor, then a perineal transanal approach while patient in lithotomy position was used to transect the distal neorectum at the level of dentate line and above the diseased segment or previous failed anastomosis, the specimen was

pulled through the anus leaving an exteriorized colonic stump measuring 6 – 10cm and tied with 2 stitches to the perineal skin, and covered with a gauze soaked with saline and daily checked for its viability. In the interval between both stages, the patients resumed low residue diet.

Second stage:

It is performed 10-15 days with patient in lithotomy position under general or spinal anesthesia with 8 stitches between the interior of the anal canal and skin at anal verge in case of absence of Lone Stare retractor.

After tying off the mesocolon at the level of the anal verge, the colonic pull-through segment was cut, to preserve the adhesions between the colonic serosa and the anal canal, hand-sewn colo-anal anastomosis was then performed using interrupted absorbable sutures (3/0 Vicryl) (fig. 3a), and sometimes it was not necessary to take stitches and just debridement of the excess colon at the level of pectinate line was enough (fig. 3b).

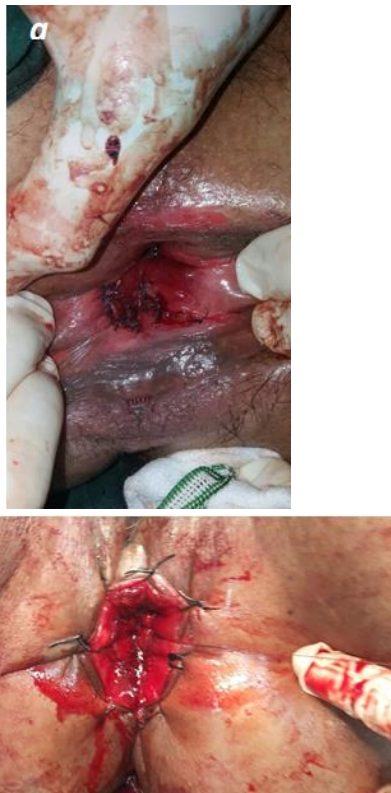

Fig. (3): Delayed colo-anal anastomosis stitches after excision of the excess colonic stump (a), spontaneous sloughing of the excess colonic stump with just debridement of the residual stump at the level of pectinate line (b).

The surgeon digitally assessed the integrity of the anastomosis at discharge. Follow up was encouraged every 2 weeks for 2 months in outpatient clinic after discharge, and recording was done for postoperative complications (surgical and/or medical complications taking place within the postoperative 30 days including infections, sepsis, and need for surgical reintervention), postoperative mortality (death occurring within the postoperative 30 days) and failure of the technique (defined as the performance of a definitive stoma)

RESULTS

Ten patients (7 men and 3 women) has underwent transanal colonic pull-through with delayed colo-anal anastomosis as a salvage procedure to avoid permanent or temporary stoma. Indication of surgery were shown in table (1). One female with history of post labor rectovaginal fistula with 3 attempts done before for repair but failed. One patient with mid rectal cancer, with misfire of the stapling device during low colorectal anastomosis, and due to the long-time procedure and high BMI (>45%), immediate colorectal anastomosis was so difficult with expected high incidence of leakage. Five patients with disrupted low colorectal anastomosis after low anterior resection for rectal cancer inspite of trial of treatment including initial fecal diversion or drainage

Three patients with history of sizable complete rectal prolapse; one of them suffered from disruption of the colo-anal anastomosis with necrosis of the proximal colon after perineal transanal rectosigmoidectomy, in the other 2 patients, colonic pull-through with delayed colo-anal anastomosis was decided from the start; one due to massive sepsis and the other due to inability to do immediate colo-anal anastomosis due to technical difficulty (BMI = 42%).

Mean operative time was 134 (115 - 215) min, 22 (15 - 48) min for both 1st and 2nd stages respectively. No mortality occurred in the study in either stages, DCA was completed in 8 patients (80%) while diversion was done in 2 patients in whom massive stump necrosis with severe infection related to anal sphincter complex occurred. Postoperative complications (table 2) included:

- One patient suffered a pelvic abscess, treated by radiologic guided aspiration
- Two patients suffered a perineal abscess treated by drainage
- One patient suffered an infection at site of colo-anal anastomosis, treated by diverting ileostomy for 8 weeks which succeeded to control the infection.

Table (2): Shows postoperative complications

Complication	Number	Management
Massive colonic stump necrosis Anal sphincter complex infection	2 (20%)	Abdominoperineal resection with permanent colostomy
Pelvic abscess	1 (10%)	U/S guided aspiration
Perineal abscess	2 (20%)	Drainage
Infection at colo-anal anastomosis	1 (10%)	Ileostomy for 8 weeks

Failure rate of the procedure to avoid definitive stoma was 20% (the 2 patients with massive necrosis of the colonic stump and sepsis destructing the anal sphincter complex)

DISCUSSION

Despite the advance in technology of colonic anastomosis surgery, still retain chance of failure (leakage), the incidence of leakage is inversely proportional to the distance of an anastomosis from the anus ^[1,4,13]. Transanal pull-through followed by delayed colo-anal anastomosis was described in 1961 ^[4, 5]. Studies have described its use for challenging and complicated colorectal conditions, with less complications in comparison to immediate colo-anal anastomosis^[4,12]. Explanation of the pull-through with DCA superiority over immediate colo-anal anastomosis was assumed to:

1. 1st at the end of first surgical stage, the pulled through colon is free from attachments in the anal sphincter, consequently, the pelvic floor rises up after the effects of curarisation disappear and there is no anastomotic tension as opposed to immediate colo-anal anastomosis
2. 2nd, before the DCA is performed, the pulled through colon and the anal canal have already started to circumferentially adhere to each other decreasing the risk of fistulae formation.
3. 3rd the risk of anastomotic leakage due to early necrosis of the descending colon by vascular occlusion of the Riolan's arcade is theoretically lower as the colonic stump is daily inspected and any necrosis appears, we can excise it and another surgery of pull-through can be offered ^[7, 12].

In this study, we evaluated the results of transanal colonic pull-through with DCA in 10 patients with success rate (80%), while 2 patients (20%) needed permeant colostomy (abdominoperineal resection), where they suffered massive colonic stump necrosis.

Six patients (60%) showed relative ischaemia and sometimes localized necrosis (2 patients) of the distal colonic stump but not extending to the colon at the level of the anal verge. This could be explained by pressure exerted by the anal sphincter complex which likely led to a relative ischemia of the exposed colon. This picture was not so evident in 2 patients, with complete rectal prolapse due to relative hypotonia of the anal sphincter complex.

In 1996, Baulieux and his colleagues reported the use of DCA for treatment of low rectal carcinoma, that received radiotherapy with no anastomotic leakage in 24 patients ^[6, 14]. Jarry and his colleagues in 2011 reported 2% leak and 6% pelvic abscess in case of immediate colo-anal anastomosis ^[12]. Remzi and his colleagues used DCA for salvage purposes in 44 patients, with decreased incidence of leakage and pelvic abscess in cases of DCA than those in immediate anastomosis; 3% versus 7%, (P<0.05) for leakage, 0% versus 5%, (P<0.05) for pelvic abscess, respectively ^[14].

Also, Hallet et al. in 2014 concluded that DCA is safe and could be offered to patients with complex colorectal conditions and low rectal anastomosis complications ^[4, 15].

7 days (range, 5–10) was mean interval between the 2 stages of the operation in the systematic review of literature ^[15], this was 11 days (10–12) in our study and 10 days (8–12) in Hallet et al, study in 2014^[4].

As our procedure resulted in straight colo-anal anastomosis, functional assessment of the anastomosis should be considered but this was not our concern in this study, colonic J pouch or transverse coloplasty has been demonstrated to offer less daily bowel movement and fecal urgency after rectal resection than staged colo-anal anastomosis^[16].

CONCLUSION

In spite of the limited number of patients in this study, transanal colonic pull-through with delayed colo-anal anastomosis technique could offer a comprehensive solution for patients with complex colorectal conditions, and could be an effective way to avoid diversion with an excellent overall outcome afterwards. Although, functional and long term results of the old “new” technique should be assessed through further large volume studies.

REFERENCES

1. Yik-Hong Ho, (2006): Techniques for restoring bowel continuity and function after rectal cancer surgery. *World J Gastroenterol*; 12(39):6252-6260.
2. Griffen FD, Knight CD Sr, Whitaker JM, et al., (1990): The double stapling technique for low anterior resection. Results, modifications, and observations. *Ann surg*; 211:745-751; discussion 751-752.
3. Gillen P and Peel AL. (1986): Comparison of the mortality, morbidity and incidence of local recurrence in patients with rectal cancer treated by either stapled anterior resection or abdominoperineal resection. *Br J Surg*; 73:339-341.
4. Hallet J, Bouchard A, Drolet S, et al., (2014): Anastomotic salvage after rectal cancer resection using the Turnbull-Cutait delayed anastomosis. *Can J Surg*; 57(6):405-411.
5. Turnbull RB Jr, Cuthbertson A. (1961): Abdominorectal pull-through resection for cancer and for Hirschsprung's disease. *Cleve Clin Q*; 28:109-115.
6. Baulieux J, Olagne E, Ducerf C, et al., (1999): Oncologic and functional results of resections with direct delayed colo-anal anastomosis in previously irradiated cancers of the lower rectum. *Chirurgie*; 124:240-250.
7. Prete F and Prete FP, (2013): The pull-through: back to the future. *G Chir*; 34(11-12):293-301.
8. Batignani G, Monaci I, Ficari F, et al., (1991): What affects continence after anterior resection of the rectum? *Dis colon rectum*; 34:329-335.
9. Marie N, Fleming T, Robinson M, Thomson B, Graetz N, Margono G, et al. Global, regional, and national prevalence of overweight and obesity in children and adults during 1980—2013: a systematic analysis for the Global Burden of Disease Study 2013. *Lancet*. 2014;384(9945):766–81.
10. Saiganesh H, Stein DE, Poggio JL (2015): Body mass index predicts operative time in elective colorectal procedures. *J Surg Res*; 197(1):45-9.
11. He Y, Wang J, Bian H, et al., (2017): BMI as a predictor for perioperative outcome of laparoscopic colorectal surgery: a pooled analysis of comparative studies. *Dis Colon Rectum*; 60(4):433-445.
12. Jarry J, Faucheron JL, Moreno W, et al., (2011): Delayed colo-anal anastomosis is an alternative to prophylactic diverting stoma after total mesorectal excision for middle and low rectal carcinomas. *Eur J Surg Oncol*; 37(2):127-33.
13. Martling A, Cedermark B, Johansson H, et al., (2002): The surgeon as a prognostic factor after the introduction of total mesorectal excision in the treatment of rectal cancer. *Br J Surg*; 89:1008-1013.
14. Remzi FH, El Gazzaz G, Kiran RP, et al., (2009): Outcomes following Turnbull-Cutait abdominoperineal pull-through compared with colo-anal anastomosis. *Br J Surg*; 96:424-9.
15. Hallet J, Milot H, Drolet S, et al., (2014): The clinical results of the Turnbull-Cutait delayed colo-anal anastomosis: a systematic review. *Tech Coloproctol*; 18:579-90.
16. Heriot AG, Tekkis PP, Constantinides V, et al., (2006): Meta-analysis of colonic reservoirs versus straight colo-anal anastomosis after anterior resection. *Br J Surg*; 93:19-32.